

## Asymmetric ocular manifestations in a premature infant with Candidemia

Chorioretinitis and lens abscess due to Candidemia

Ayşegül Arman<sup>1</sup>, İkbâl Seza Petriçli<sup>2</sup>, Caner Kara<sup>2</sup>, Ayşen Sumru Kavurt<sup>3</sup><sup>1</sup>Department of Ophthalmology, Bilkent City Hospital<sup>2</sup>Department of Ophthalmology, Etlik Zübeyde Hanım Women's Health Education and Research Hospital<sup>3</sup>Department of Neonatology, Etlik Zübeyde Hanım Women's Health Education and Research Hospital, Ankara, Turkey**Abstract**

Candidemia can cause candida chorioretinitis, candida endophthalmitis, and, rarely, candida lens abscess in premature infants. Here, we describe a case of a premature infant with leukocoria and chorioretinitis, presumed to be caused by candidemia. The patient was diagnosed with systemic candidiasis after the growth of *C. albicans* in the blood culture done for septic work up because of a deterioration of his general condition. Ophthalmological evaluation revealed minimal ciliary injection, lens abscess and shallow anterior chamber in the left eye, and chorioretinitis in the right eye at 3rd week of life. The infant developed multiorgan failure and died on the 28th day of life. A dilated ophthalmological examination should be performed in all patients with candidemia within the first week of treatment. Although rarely seen, candida lens abscess should be kept in mind in the differential diagnosis of lens opacities in premature infants.

**Keywords**

Abscess; Candida; Chorioretinitis; Endophthalmitis; Lens

DOI: 10.4328/ACAM.20569 Received: 2021-03-08 Accepted: 2021-04-17 Published Online: 2021-05-11 Printed: 2021-09-01 Ann Clin Anal Med 2021;12(9):1080-1082

Corresponding Author: Caner Kara, Etlik Zübeyde Hanım Women's Health Education and Research Hospital, Department of Ophthalmology, Yeni Etlik Caddesi No: 55, 06010, Etlik, Keçiören, Ankara, Turkey

E-mail: canerkara@hotmail.com P: +90 (312) 567-4679 F: +90 (312) 322-0184

Corresponding Author ORCID ID: <https://orcid.org/0000-0002-3628-547X>

Introduction

Candida species are important nosocomial pathogens in neonatal intensive care units (NICU). Preterm infants with gestational age  $\leq 32$  weeks and birth weights  $\leq 1000$ g are especially at risk of systemic candidiasis. Common practices in NICU's, indwelling catheters and endotracheal tubes put the preterm infant at risk of invasive candidiasis [1]. Other risk factors are sepsis, abdominal surgeries, malnutrition, treatment with broad spectrum and multiple antibiotics and total parenteral nutrition [2]. Colonization of the skin and gastrointestinal tract is the first step in the pathogenesis with the adherence of candida to mucosal and dermal epithelial cells, and hematogenous spread is the second step [3]. Infection of the eye results from hematogenous seeding during candidemia and may result in chorioretinitis, endophthalmitis, and, rarely, lens abscess.

Here, we report a premature infant with late onset candidemia and asymmetric ocular involvement at 3rd week of life.

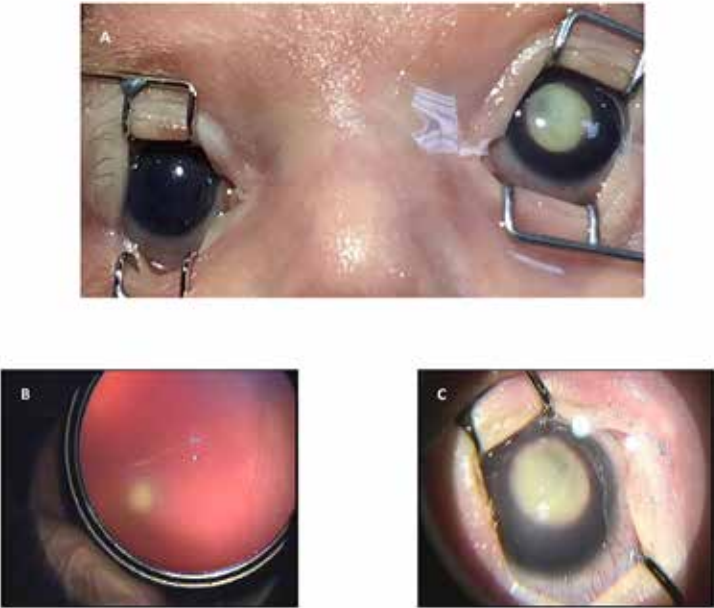
Case Report

The 975-g male infant was consulted at the NICU of Etlik Zübeyde Hanım Woman Health Training and Research Hospital at 28 weeks postmenstrual age to be evaluated for a fungal eye infection. The infant was born at 25<sup>4/7</sup> weeks of gestation to a 34-year-old mother by cesarean section due to preterm labor and previous cesarean delivery. Apgar scores were four and eight in the first and fifth minutes, respectively. The patient was intubated in the delivery room and admitted to the NICU. He received two doses of surfactant for respiratory distress syndrome. On the first day, a central venous catheter (CVC) was inserted through which penicillin and gentamicin were administered for three days. Parenteral nutrition was started. Gradually, respiratory distress improved and the baby was weaned from continuous positive airway pressure (CPAP) on the fifth postnatal day. On the eighth day of life, the baby had recurrent episodes of prolonged apnea with desaturation and was evaluated for suspected sepsis. Empiric antibiotherapy with cefotaxime and amikacin was given. However, he deteriorated gradually, and was started on invasive ventilation because of poor respiratory efforts prompting another septic work up including a new blood culture. At the 48th hour, the blood culture yielded growth of *Candida albicans*, and fluconazole was started. The CVC was removed as the source of infection. The cerebrospinal fluid (CSF) analysis was normal and the culture of CSF was sterile. Cranial ultrasound examination reported hyperechogenic lesions, and fluconazole was changed to amphotericin B. Echocardiogram, abdominal and renal ultrasound examination revealed no vegetation.

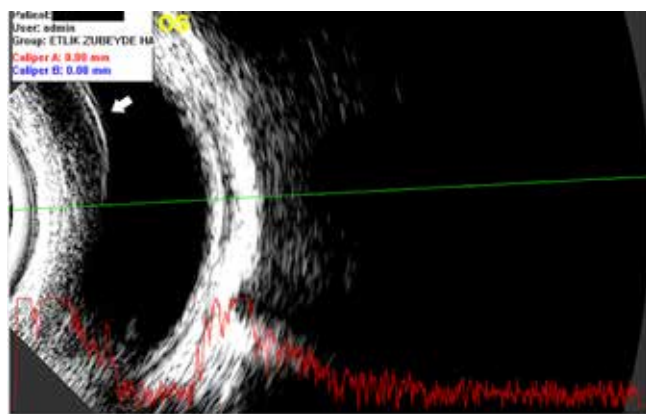
On hand-held biomicroscopic examination of the right eye, the cornea was clear, the conjunctiva was white and quiet, the anterior chamber depth was normal without hypopyon, and the lens was clear. There was not any definite sign of inflammation. On indirect ophthalmoscopic evaluation after pupillary dilation, a persistent tunica vasculosa lentis (TVL) and minimal vitreous haze with two yellow-white creamy chorioretinal lesions, half of the optic disc diameter with ill-defined margins were detected in the temporal mid-periphery (Figure 1). Retina was immature and avascular in Zone 2 and Zone 3. On the hand-

held biomicroscopic evaluation of the left eye, the cornea was clear, the conjunctiva was hyperemic with minimal ciliary injection, the anterior chamber was shallow without hypopyon and the lens was swollen with a total creamy white lens opacity (Figure 1). Complete fluffy opacification of the lens with signs of ocular inflammation and shallowing of the anterior chamber was considered as lens abscess. The pupillary red reflex was absent, and after pupillary dilation, retina could not be visualized. Intraocular pressure was 15mmHg for the right eye and 31mmHg for the left eye. B-scan ultrasonographic (USG) evaluation of the left eye revealed an enlarged lens extending into the anterior vitreous and no definitive retinal detachment (Figure 2). B-scan USG evaluation of the right eye revealed a normal lens and an attached retina. The initial diagnosis was persistent TVL with presumed candida lens abscess of the left eye and candida chorioretinitis of the right eye. During antifungal therapy, *C. albicans* was identified in the second blood culture, and amphotericin B treatment was switched to micafungin.

We planned to refer the infant for an intravitreal injection of micafungin into the left eye, but the infant's condition deteriorated gradually. Supportive treatment as packed cell transfusion for anemia and platelet transfusion for thrombocytopenia was done. The infant gradually developed generalized sclerema, oliguria and despite the intense treatment, the patient died on the 28 day of life due to multiorgan failure. Written informed consent for the publication of this case report has been obtained from a parent of the infant.



**Figure 1.** (A). External image of both eyes showing leukocoria in the left eye and a normal appearance in the right eye. (B). Fundus photo of the right eye as seen by indirect ophthalmoscopy showing chorioretinitis and minimal vitreous haze (C). Anterior segment photo of the left eye showing lens abscess, minimal ciliary injection.



**Figure 2.** B-scan ultrasonography of the patient's left eye showing an enlarged lens extending into the anterior vitreous (white arrow) and no definitive retinal detachment.

## Discussion

Candidemia is the most common cause of endogenous endophthalmitis and can cause candida chorioretinitis with choroidal and retinal lesions, and candida endophthalmitis characterized by chorioretinitis with vitritis [4-6]. Lens involvement is very rare [7,8]. A dilated ophthalmologic examination should be performed on all patients with candidemia according to the Infectious Disease Society of America guidelines [9]. This case is a late-onset endogenous candida eye infection detected at the 3rd week of life after the initiation of treatment for candidemia in an extremely premature infant. This infant had multiple risk factors for systemic candidiasis, including severe prematurity, low birth weight, intravenous catheter, endotracheal tube, total parenteral nutrition, and broad-spectrum antibiotherapy.

During embryologic development, the lens is supplied with blood from the hyaloid artery, which approaches the lens from the posterior and supplies a network of vessels called tunica vasculosa lentis (TVL). The hyaloid artery regresses later in gestation followed by the regression of TVL. Birnholz et al. [10] found that patent hyaloid artery was not seen beyond 29.9 weeks of gestation. These findings were corroborated with a power Doppler US study by Achiron et al. [11]; they showed that HA regression is a gradual process, and beyond 29 weeks of gestation, HA could not be detected. Patent hyaloid artery system in a preterm infant may allow the fungus to be sequestered in the lens during candidemia. We supposed that the lens opacity in the left eye was caused by the invasion of fungi through the patent HA system. The chorioretinitis in the right eye is caused by the invasion of fungi through the developing retinal and choroidal vasculature. The infant had asymmetric involvement of the eyes, which may be due to the difference in the proximity of the eyes to direct arterial blood flow and patency of the HA system. Although candida lens abscess is a very rare complication of systemic candidiasis, we thought that the growth of less-sensitive fungal strains in serial blood cultures, despite fluconazole and amphotericin-B treatment allowed fungi to be sequestered in the lens and to progress into total lens abscess. In addition, the swollen lens had led to shallowing of the anterior chamber and an increase of the intraocular pressure.

## Conclusion

Candida species are a frequent cause of sepsis in premature infants. Dilated eye examinations should be performed within the first week of antifungal treatment. In the presence of candidemia, all cases of neonatal endophthalmitis should be accepted as candidal in etiology. In addition, candidal lens abscess should be kept in mind in the differential diagnosis of lens opacities in premature infants.

## Scientific Responsibility Statement

The authors declare that they are responsible for the article's scientific content including study design, data collection, analysis and interpretation, writing, some of the main line, or all of the preparation and scientific review of the contents and approval of the final version of the article.

## Animal and human rights statement

All procedures performed in this study were in accordance with the ethical standards of the institutional and/or national research committee and with the 1964 Helsinki declaration and its later amendments or comparable ethical standards. No animal or human studies were carried out by the authors for this article.

## Conflict of interest

None of the authors received any type of financial support that could be considered potential conflict of interest regarding the manuscript or its submission.

## References

1. Kaufman D. Strategies for prevention of neonatal invasive candidiasis. *Semin Perinatol.* 2003;27(5):414-24.
2. Narang A, Agrawal PB, Chakrabarti A, Kumar P. Epidemiology of systemic candidiasis in a tertiary care neonatal unit. *J Trop Pediatr.* 1998;44(2):104-8.
3. Bendel CM. Colonization and epithelial adhesion in the pathogenesis of neonatal candidiasis. *Semin Perinatol.* 2003;27(5):357-64.
4. Baley JE, Ellis FJ. Neonatal candidiasis: ophthalmologic infection. *Semin Perinatol.* 2003;27(5):401-5.
5. Fierro JL, Prasad PA, Fisher BT, Gerber JS, Coffin SE, Walsh TJ, et al. Ocular manifestations of candidemia in children. *Pediatr Infect Dis J.* 2013;32(1):84-6.
6. Oude Lashof AM, Rothova A, Sobel JD, Ruhnke M, Pappas PG, Viscoli C, et al. Ocular manifestations of candidemia. *Clinical Infectious Diseases.* 2011;53(3):262-8.
7. Drohan L, Colby CE, Brindle ME, Sanislo S, Ariagno RL. Candida (amphotericin-sensitive) lens abscess associated with decreasing arterial blood flow in a very low birth weight preterm infant. *Pediatrics.* 2002;110(5):e65.
8. Couser NL, Hubbard GB, Lee LB, Hutchinson AK, Lambert SR. Candida species lens abscesses in infants with a history of neonatal Candida sepsis. *Journal of AAPOS : the official publication of the American Association for Pediatric Ophthalmology and Strabismus.* 2013;17(2):208-10.
9. Pappas PG, Kauffman CA, Andes DR, Clancy CJ, Marr KA, Ostrosky-Zeichner L, et al. Executive Summary: Clinical Practice Guideline for the Management of Candidiasis: 2016 Update by the Infectious Diseases Society of America. *Clin Infect Dis.* 2016;62(4):409-17.
10. Birnholz JC, Farrell EE. Fetal hyaloid artery: timing of regression with US. *Radiology.* 1988;166(3):781-3.
11. Achiron R, Kreiser D, Achiron A. Axial growth of the fetal eye and evaluation of the hyaloid artery: in utero ultrasonographic study. *Prenat Diagn.* 2000;20(11):894-9.

## How to cite this article:

Ayşegül Arman, İkbâl Seza Petriçli, Caner Kara, Ayşen Sumru Kavurt. Asymmetric ocular manifestations in a premature infant with Candidemia. *Ann Clin Anal Med* 2021;12(9):1080-1082